

# SEMINARS IN ARTHRITIS & RHEUMATISM

## Proceedings from the 5th Annual International Society for Musculoskeletal Imaging in Rheumatology Annual Conference

Philip G. Conaghan, MD, PhD, Mikkel Ostergaard, MD, PhD,  
Maria Antonietta D'Agostino, MD, PhD, Norman Gaylis, MD,  
William Arnold, MD, Ewa Olech, MD, Alvin Wells, MD, PhD,  
Charles Peterfy, MD, PhD, Judy L. Seraphine, and Orrin Troum, MD

# Proceedings from the 5th Annual International Society for Musculoskeletal Imaging in Rheumatology Annual Conference

Philip G. Conaghan, MD, PhD,\* Mikkel Ostergaard, MD, PhD,<sup>†</sup>  
 Maria Antonietta D'Agostino, MD, PhD,<sup>‡</sup> Norman Gaylis, MD,<sup>§</sup> William Arnold, MD,<sup>¶</sup>  
 Ewa Olech, MD,<sup>#</sup> Alvin Wells, MD, PhD,<sup>\*\*</sup> Charles Peterfy, MD, PhD,<sup>††</sup>  
 Judy L. Seraphine,<sup>§§</sup> and Orrin Troum, MD<sup>‡‡</sup>

Since its inception, ISEMIR has held an annual education meeting highlighting the changes in the utilization of imaging tools for the management of rheumatic diseases. ISEMIR's international faculty and world-renowned experts have discussed these topics at a very high scientific level. The evolution of the content demonstrates the rapidly changing environment in the field of rheumatology. Advances in treatment have led to the increased use of magnetic resonance imaging (MRI) and ultrasound (US). This publication is based upon the proceedings from the 2012 ISEMIR educational meeting that took place on April 26th in Chicago, Illinois. Presentations from the live proceedings can be viewed at [www.isemir.org](http://www.isemir.org).

© 2012 Elsevier Inc. All rights reserved. *Semin Arthritis Rheum* 42:433-446

The role of magnetic resonance imaging (MRI) and Ultrasound (US) has expanded significantly over the last several years for the management of musculoskeletal diseases; however, these techniques are often times under-utilized in clinical practice despite the data supporting the benefits of their use from both a diagnostic and therapeutic management standpoint. Clinicians should not make the mistake of limiting MRI to rheumatoid arthritis (RA), which only accounts for 20% of medical visits, as MRI can be utilized in many other rheumatic conditions. In fact, numerous studies have demonstrated that MRI and Ultrasound can aid physicians in the diagnosis of various rheumatic

conditions and can help guide treatment decisions that will ultimately optimize patient outcomes.

## REVIEW OF THE RECENT MRI LITERATURE

*Philip Conaghan, MD*

The MRI literature continues to grow at a rapid rate across a range of disease areas and some highlights over the last year or two will be presented. The most extensive literature is in the rheumatoid arthritis (RA) field and this is discussed in more detail in other parts of this Proceedings.

## Rheumatoid Arthritis Clinical Trials

Certainly the need for a sensitive assessment of RA structural progression remains paramount, especially when modern ethical trial design makes the use of placebo for prolonged periods of time impossible. This means radiographic studies have to differentiate between two active treatment arms. A recent systematic literature review has suggested that recent trials have enrolled RA patients with lower disease activity than in the past (1).

An increasing number of trials, both phase II and III, have included MRI, sometimes as primary outcome. These trials have been summarized in a recent review (2) but this is a rapidly growing field. A range of agents have been evaluated though caution must be taken in comparing across trials

\*University of Leeds, Leeds, United Kingdom.

<sup>†</sup>Copenhagen University Hospital at Hvidovre and Herly, Copenhagen, Denmark.

<sup>‡</sup>University of Versailles Saint-Quentin-en-Yvelines Ambroise Pare Hospital, Boulogne-Billancourt, France.

<sup>§</sup>President, Arthritis and Rheumatic Disease Specialties, Aventura, FL.

<sup>¶</sup>Keck School of Medicine, University of Southern California, Santa Monica, CA.

<sup>#</sup>Illinois Bone and Joint Institute, Morton Grove, IL.

<sup>\*\*</sup>University of Nevada School of Medicine, Las Vegas, NV.

<sup>\*\*</sup>Rheumatology and Immunotherapy Center, Franklin, WI.

<sup>††</sup>Founder and CEO, Spire Sciences, LLC, San Francisco, CA.

<sup>§§</sup>The International Society for Musculoskeletal Imaging in Rheumatology, West Hartford, CT.

Address reprint requests to Philip G. Conaghan, Division of Musculoskeletal Disease, Chapel Allerton Hospital, Leeds LS7 4SA, UK. E-mail: [p.conaghan@leeds.ac.uk](mailto:p.conaghan@leeds.ac.uk)

The OMERACT-EULAR sonography group is working on a reliable, standardized scoring system for tenosynovitis in RA. This scoring system includes a tendon and synovial tendon sheath involvement that combines together gray scale and Doppler and is consistent between machines.

Ultrasound requires further standardization with regard to scoring erosions and detecting their severity.

## Summary

A significant body of literature has addressed the impact of musculoskeletal US on the care of patients with rheumatic diseases, especially RA. Ultrasound provides clinical utility for differential diagnoses and clinical prediction, follow-up assessment and daily management. The role of US in the diagnosis and management of rheumatologic diseases has evolved significantly in recent years and US offers complementary and/or superior assessment over conventional methods with substantial potential benefits. US is a safe technique, but technological limitations and possible misclassifications exist. Further validation is necessary for the implementation of US in clinical practice and trials.

## THE UTILIZATION OF MRI IN RHEUMATOLOGY PRACTICE

*Norman B. Gaylis, MD, FACP, FACR*

It is important to note, that there are two streams regarding the utilization of MRI and US in the world of Rheumatology. Both of these tools are critical when making treatment decisions for patients with musculoskeletal disease and while monitoring their disease progression.

Over the last decade, Rheumatologists have seen a heightened awareness among patients and physicians regarding the diagnosis and therapeutic choices for RA and other rheumatic diseases. We know that traditional radiography may show slowing of progressions of erosions when compared with a control group; yet, because MRI provides greater sensitivity than clinical examination and radiography for assessing disease activity, it is an improved means for both early diagnosis of rheumatic diseases and assessing treatment response. MRI demonstrates changes in synovitis and osteitis over time, along with erosions and bone marrow edema (32).

### Bone Edema, Bone Erosions and Synovitis

Several studies demonstrate that MRI bone edema corresponds with regions of inflammation when comparing MRI slices with histological sections. One study in particular looked at RA patients, scheduled for joint replacement surgery, who had undergone MRI on the day prior to the surgery. The researchers found that MRI bone erosions and MRI bone marrow edema are a result of the inflammatory infiltrates found in the bone marrow

of patients with RA. MRI was found to be sensitive in detecting inflammatory tissue in the bone marrow. MRI also shows the inflammatory process that extends to the bone marrow cavity. These results demonstrate an additional target structure for anti-inflammatory therapy (33).

Many Rheumatologists question whether or not the "disconnect" between synovitis and erosion in RA is a result of the treatment or due to the disease in itself (34). In various studies, subclinical inflammation on MRI was identified in the majority of patients who were in clinical remission or a state of low-disease activity. By using these MRI findings, clinicians can more effectively choose therapies that may improve patient outcomes.

High scores for all MRI features combined (synovitis, bone edema, tenosynovitis and erosions) indicate poor prognosis. Bone edema seems to be a major predictor of erosive disease. Data from a cohort of 42 patients illustrate that the baseline MRI bone edema score of the dominant wrist increases erosion risk by 6.5 times. The largest and most recent data set comes from the CIMESTRA study, which incorporated baseline MRI scans into the protocol. When looking at potential prognostic markers (DAS28, anti-CCP, shared-epitope, smoking status, x-rays and MRI findings), bone edema at the hand and wrist was the strongest independent predictor of radiographic progression after two years (35–37).

### Low-field MRI versus Conventional MRI

There are many advantages and disadvantages when looking at low-field MRI versus conventional MRI. Some of the advantages include the fact that a radio frequency-shielded room is not required, the positioning is normally much more comfortable for patients, the site preparation is rather easy, and there is the convenience of an in-office procedure; therefore, wasting less time. The disadvantages of low-field MRI are a lower spatial resolution, a smaller field of view, longer imaging time, and a reduced number of possible imaging techniques (38). Healthcare providers should be aware that a 1.5-tesla MRI and 0.2-tesla MRI are diagnostically equivalent (Table 1).

### Using Imaging Modalities to Determine Treatment Choices

Right now and looking forward, using MRI and US findings, gives healthcare providers the ability to make early diagnoses and early treatment decisions in order to help guide treatment choices that may lead to different treatment options or down-regulation of the current treatment. The detection of synovitis may lead one to choose a TNF inhibitor; whereas osteitis may determine the use of a B-cell modulator (34).

As clinicians, it is important to keep in mind several factors when monitoring RA patients with MRI. MRI is more sensitive than radiographs in detecting structural

Table 1 RA in the Hand/Wrist: Comparison of Three Imaging Techniques.

- Conventional high-strength MRI (1.5 T)
- Low-field-strength dedicated EMRI (0.2 T)
- Conventional X ray hand/wrists
- Two blinded radiologists: N 18
- Measurement using Sharp/Genant scoring system; erosion (E), synovitis (S), joint-space narrowing (J).

	E	S	J
<b>MRI High-Field (HF)</b>	+++	++	+++
<b>MRI Low-Field (LF)</b>	+++	++	+++
<b>X ray</b>	+	0	++

- Interobserver agreement good to excellent.
- Low cost, patient compliant, LF dedicated E MRI provides similar information on bone erosions and synovitis as expensive HF MRI units.

(Adapted from: Taouli B, et al. *Am J Roentgenol.* 2004;182:937-943 (39)).

progression; therefore, making MRI a useful tool when monitoring therapy, as structural damage may be ongoing despite pain relief, signs and symptoms. Synovitis can be detected in 96% of RA patients who are in clinical remission and 19% of these patients displayed deterioration in radiographic joint damage over one year. It appears that MRI findings correlate with disease activity, and scores fail in response to therapy (40–44).

### Future Use of MRI in a Changing Treatment Landscape for RA

The paradigm of RA treatment has changed immensely over the last sixty years. Up until 1996, clinicians tended to wait for erosions and disability to occur prior to treatment. With the approval of the biologics in the late nineties, clinicians began to look more at erosions and joint space narrowing when managing RA patients. As the below illustration, Figure 1, speculates, the utilization of MRI and/or US findings may be a more appropriate way of determining treatment choices for patients prior to the occurrence of structural damage, and ultimately the tapering or downscaling of treatment.

There are several published RA clinical trials using MRI as an outcome measure. All of the studies demonstrate efficacy of therapies in a short time and with small numbers of patients. In the Quinn et al. study of 20 early RA patients, significant suppression of inflammation at 14 weeks and prevention of erosions at two years was observed in the infliximab/methotrexate-treated patients versus placebo/methotrexate-treated patients as assessed by MRI. In another study with only 22 patients, changes in synovitis in the etanercept group showed significant reduction at six weeks compared with no changes in the control group (45).

Forty-four patients with early RA were randomized to receive methotrexate alone, methotrexate plus IV MP or

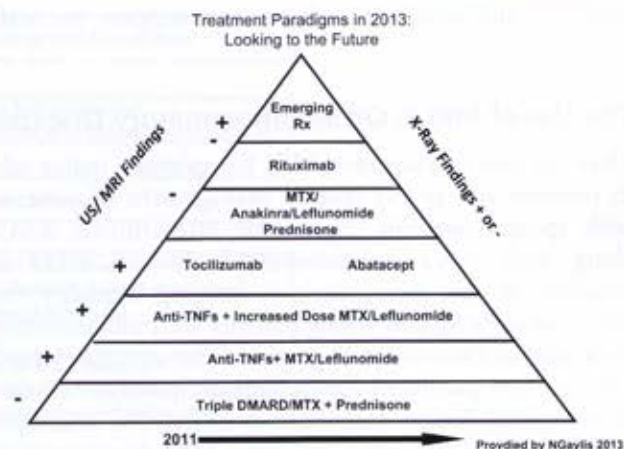


Figure 1 MTX methotrexate; TNF tumor necrosis factor; Rx therapy.

methotrexate plus infliximab. Significantly lower synovitis scores in the infliximab group compared with the methotrexate group were found. Also, there were significantly lower bone edema scores in the infliximab group compared with the methotrexate and the IV MP groups (46).

Thirteen patients with refractory RA treated with adalimumab were examined with MRI of the dominant affected wrist and hand before treatment and one year after therapy. The volume of the enhanced inflammatory tissue after treatment were significantly lower compared to the corresponding values before treatment (47).

A multicenter, randomized, double-blind, placebo-controlled, phase II study evaluated the effects of denosumab on structural damage in patients with RA receiving methotrexate treatment. At six months, the increase in the MRI erosion score from baseline was lower in the 60-mg denosumab group, and was significantly lower in the 180-mg denosumab group than in the placebo group (47).

Of note, all these studies were conducted using whole-body MRI systems.

### Implementing MRI in Clinical Practice

Upon deciding to utilize MRI in the clinical setting, it is important that clinicians review all specifications and the costs associated with the system. Office space is an important consideration regarding patient/staff flow. It is also extremely important to review one's monthly referral volume, i.e., the body part to be examined and verify that the referral volume supports the decision to implement the use of MRI in the office. A financial proforma should be created regarding financial choices and the option of leasing versus purchasing. Several other factors include a contract with the vendor, installation time, contracting with a radiologist to conduct the

readings, and adequate training and support for staff members.

### The Use of MRI in Other Inflammatory Diseases

Over the past two decades, MRI has gained a major role in research and in the clinical management of patients with spondyloarthritis (SpA) and osteoarthritis (OA), along with other musculoskeletal diseases. MRI is regarded as the most sensitive imaging modality for detecting early SpA in young patients with inflammatory back pain and normal radiographs of the sacroiliac joints. The recently published Assessment of SpondyloArthritis International Society classification criteria for axial SpA include, for the first time, a positive MRI demonstrating sacroiliitis as an imaging criterion indicative of SpA together with at least one clinical feature of SpA (49).

In knee OA, bone lesions on MRI are strongly associated with the presence of pain and bone marrow edema, a strong risk factor for structural deterioration. According to OARSI, MRI changes of OA may occur in the absence of radiographic findings of OA and MRI may add to the diagnosis of OA.

In psoriatic arthritis (PsA), advances in imaging techniques have led to their increased use when assessing the efficacy of novel therapies. MRI has an increased use in PsA with regards to diagnosis, monitoring, prediction of disease course, and treatment response.

### Summary

The utilization of MRI in clinical practice has enabled Rheumatologists to better care for their patients through earlier diagnoses and an improved means for monitoring disease progression.

### INTERSOCIETAL ACCREDITATION COMMISSION (IAC)

*Orrin Troum, MD*

Modern imaging has become mainstream in rheumatology training and practice, specifically the use of US and MRI. Standardizing quality images and interpretation is crucial for both the rheumatologist and patient. Accreditation is a process of both internal and external evaluation to accurately assess level of performance in relation to established standards.

The purpose of the IAC MRI accreditation program is "to ensure high quality patient care and to promote health care by providing a mechanism to encourage and recognize the provision of quality MRI diagnostic evaluations by a process of accreditation". Through this process, facilities assess every aspect of daily operation (its impact on the quality of health care provided to patients, procurement of a safe environment, and educating themselves about contraindications and associated risks involved in MR imaging). Additionally, institutions implement standard operating procedures for equipment

maintenance and performance measures, infection control, and emergency care, if needed.

IAC MRI was created in 2000 to accredit MRI facilities and has offered a pathway for those utilizing MRI to both document their quality and comply with insurers' payment policies that mandate accreditation. The most recent mandate, by Medicare, was initiated on January 1, 2012. The Medicare Improvements for Patients and Providers Act (MIPPA) requires all nonhospital providers of advanced diagnostic imaging, be accredited as a condition for reimbursement.

The importance of accreditation is that patients and payers can rely on it as an indication that the facility has proven a commitment to providing quality medical testing. Patients can rest assured that accredited facilities have been carefully critiqued on all aspects of their operations considered relevant by medical experts.

Rheumatologists have welcomed this process to be included as points of service of MR testing. Dr. Orrin Troum and Dr. Norman Gaylis, founding members of ISEMIR (International Society of Musculoskeletal Imaging), represent practicing rheumatologists utilizing MRI on the IAC MRI Board of Directors (Fig. 2).

### POINT/COUNTERPOINT—MRI VERSUS ULTRASOUND: WHICH ONE SHOULD I USE?

*Ewa Olech, MD, William Arnold, MD, Alvin Wells, MD, PhD*

Ultrasonic energy was first applied to the human body for medical purposes in the late 1940s and the first compound contact B-mode scanner was developed in 1962. The world's first MRI machine was created in 1972. Despite the fact that MRI is a much younger technique, the number of publications with MRI in rheumatic diseases is higher than with US.

MRI is a 3-D technique with no depth limit, which has the ability to assess all parts of the joints, including bone edema, cartilage and muscle inflammation. Ultrasound (US) in contrast, allows real-time, multiplanar, high resolution visualization. Operator dependency is its potential disadvantage. US Doppler provides hemodynamic information; thus no contrast is required to reliably distinguish synovium from effusion as with MRI.

Both techniques have many similar indications, such as inflammatory and crystal arthropathies, regional rheumatic pain syndromes (tendonitis, bursitis, etc), internal joint derangements (meniscal, rotator cuff tear), carpal tunnel syndrome, polymyalgia rheumatica, and temporal arteritis. However, certain disorders require use of one technique versus the other. MR is the imaging of choice for spine diseases, myopathies, osteomyelitis or avascular necrosis. US is used in scleroderma, Sjogren's syndrome, fibromyalgia, as well as for arthrocentesis and joint injections.

The cost of MRI is definitely higher than US. MRI prices start from \$200,000 for extremity systems and range more than \$2 million for some 3.0 tesla scanners. In addition, the construction of MRI suites can cost